

Removal of Ectopic Canine in Region of Mandible - Case Report

Ítalo Kennedy Silva Santos¹, Jefferson David Melo de Matos¹, Ana Larisse Carneiro Pereira¹, Antonio Jackson Andrade Gonzaga de Oliveira², Jéferson Martins Pereira Lucena Franco³, Victor Archeti Vardiero⁴ and John Eversong Lucena de Vasconcelos^{4*}

Accepted 6 July 2017

¹School of Dentistry, University Center UNILEÃO, Juazeiro do Norte, Ceará, Brazil.

²Universidade Regional do Cariri - URCA, Crato – CE, Brazil.

³Department of Oral and Maxillofacial Surgery, Hospital Geral de Fortaleza – HGF – Fortaleza, Ceará, Brazil.

⁴Professor of Implantology, Dentistry Department, Centro Caririense de Pós-Graduação CECAP, Juazeiro do Norte, Ceará, Brazil.

ABSTRACT

This study aims to present, through the report of a clinical case, the clinical characteristics and the treatment approach in an unusual pathology of an impacted lower canine. Male patient, 40 years old, feoderma, native of Juazeiro do Norte - CE, attended the dental clinic Symmetry. The same patient complained of not erupting the permanent tooth in the anterior region of the mandible, after the clinical and radiographic examination the presence of the tooth was detected. The canine exudation was performed, including bone wear, where it was accessed through a linear incision in the groove bottom. It has been observed in the literature that ectopic canines that do not have the physiological or mechanical conditions to erupt must be removed from the jaws by the high pathogenic potential of cysts and tumors development. There was a high complexity in the treatment of impacted canines, since the characteristics of the dental elements are of paramount importance for the type of treatment.

Key words: Canine tooth, Oral surgery, Nitrous oxide.

*Corresponding author. E-mail: matosjefferson19@gmail.com. Tel: +55 (88) 3512-1590/ +55 (88) 9.8802-4651/ +55 (88) 9.9712-3250.

INTRODUCTION

The impaction of the canines of the lower arch is considered an uncommon condition among the pathologies that affect the stomatognathic system, since the delayed eruption of the dental elements is one of the lesions that can affect directly and indirectly the conditions of the dental arch morphology, considered as one of the most aggravating pathologies in the transition in the modification of deciduous and permanent teeth (Agarwal et al., 2013). The treatment plan is complex and diverge from the approach of the other dental elements, where it considers the biomechanics as one of the main decisive points for orthodontic therapy. The delay of the dental eruption can determine the normal position of the teeth and when orthodontic treatment is not adequate, it is indicated

surgical therapy (Ayuse et al., 2015). The orthodontic treatment of impacted lower canines should be very poor because it presents factors that determine the biomechanics of the tooth to return to normal position. The very detailed analysis is of paramount importance, since the late eruption of the dental elements can interfere with the patient's bite, generating malocclusion. In fact, correct diagnosis and a good planning reduce the time of treatment and eliminate the possibility of derangement of the dental arch (Cozzani et al., 2013).

The approach in the impacted canine treatment plan in the mandible can be surgical, ortho- surgical and surgical. In addition to existing multiple therapy options, aspects such as the presence of a deciduous tooth is a crucial point

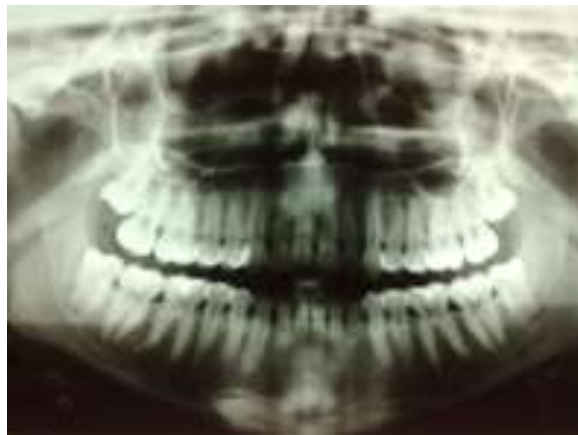

Plate 1. Orthopantomography of the patient, canine in a region near the mentum.

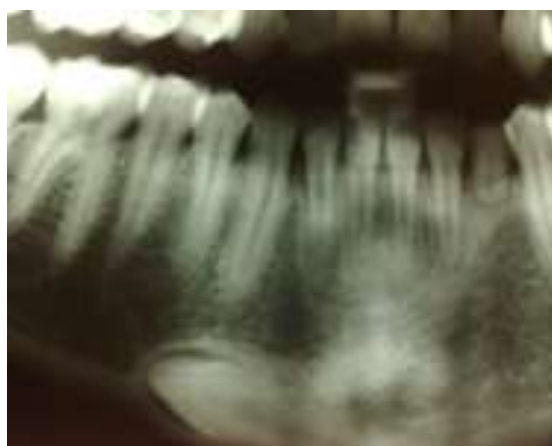

Plate 2. Orthopantomography of the patient, canine in a region near the mentum.

in the choice of surgical treatment (Curl and Boyle, 2012). Nitrous oxide is one of the forms of sedation of patients who undergo procedures in the odontological office. However, it has one of its weak points its weak action potency, most of the time being additional sedatives. In treatments in children in the dental outpatient clinic, drugs such as sevoflurane by inhalation route are showing efficacy in short and half-time dental procedures (Santos et al., 2017). Nitrous oxide presents some contraindications, among them, it is absolutely impossible to use in patients who underwent vitreoretinal surgery, where it will have an accumulation of intraocular gases. Thus, it is extremely important to know the dental surgeons' knowledge about this type of procedure in these risk patients. The communication with the patient's ophthalmologist is of utmost importance not to present postoperative complications (Lau et al., 2013). This paper aims to expose, through the report of a clinical case the clinical characteristics and treatment approach in an unusual pathology of an impacted lower canine.

CASE REPORT

Male patient, 40 years old, feoderma, native of Juazeiro do Norte - CE, attended the dental office Symmetry. The patient had a complaint that the tooth had not erupted. The tooth remained in the anterior region of the mandible. After the clinical and radiographic examination, the presence of the tooth was detected 33. The ectopic tooth was positioned horizontally in the basilar part of the mandible, presenting in the risogenesis phase, however, it did not have the physiological conditions to move to the place of normality (Plate 1). It was then proposed the surgical measure for the respective case because it should be removed from the region in which it was, the surgical treatment was performed because the tooth presents characteristics of not having biomechanical conditions in orthodontic therapy, thus the last measure It was necessary in this case death (Plate 2). Thus, an incision was made in the fundus of the groove in the anterior region of the mandible, in order to access the basilar part of the

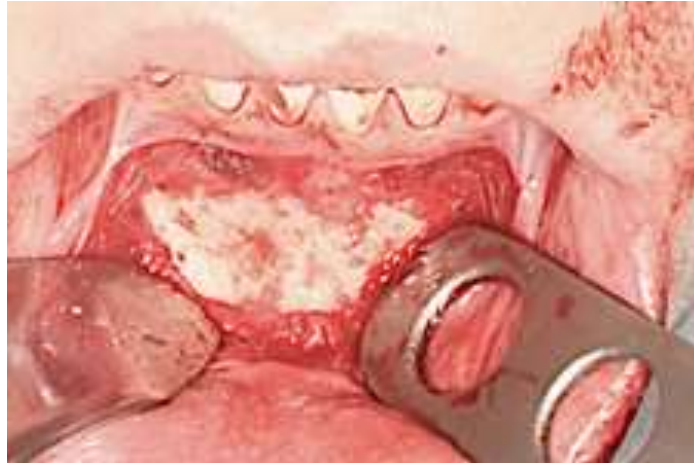

Plate 3. Exposure of the bone area, for canine removal.

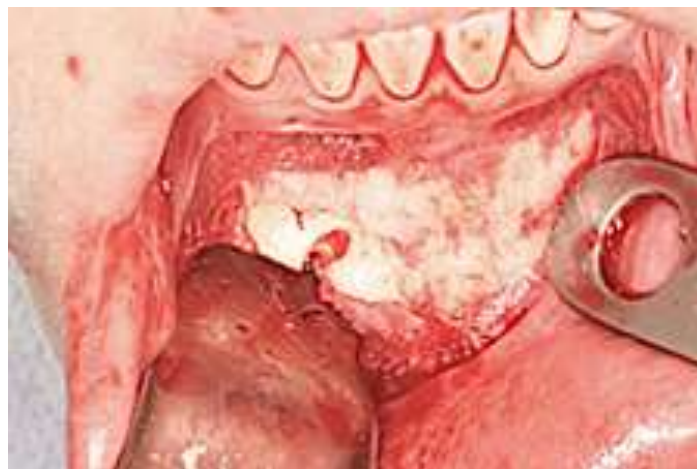

Plate 4. Exposure of the bone area, for canine removal.

mandible (Plate 3).

The proper exodontia of the dental element was through bone wear using a drill bit 702 until access to the intraosseous region that the tooth is housed (Plate 4 and 5). For the sedation of the patient, the inhalation of nitrous oxide was used, where 5 min were applied for the appropriate initial sedation and then the incremental technique was applied (Plate 6 and 7). The use of pulse oximeter before, during and after sedation was indispensable to maintain monitoring of patient oxygen levels (Plate 8 and Plate 9). The drug therapy was administered to the administration of dexamethasone 10 mg in the preoperative period and then Ibuprofen in the dosage of 300 mg, every 8 h for 3 days. Seven days after the operative procedure, it was evaluated and the repair was observed in the area where the insulation was performed and no symptomatology was reported.

METHODOLOGY

A bibliographic search was performed in the PUBMED

database (www.pubmed.gov), which it was collected by the following mesh terms: mandible, Tooth impacted, Canine and nitrous oxide presented in the abstract or body text. The following criteria were included: were developed in the human species, case report and that had year of publication between 2011 to May 2017 (Figure 1 and 2)

RESULTS

Based on the literary review, the treatment plan approach to impacted canines is quite complex and one must follow ortho-surgical, surgical or orthodontic therapy. Commonly associated pathologies may trigger dysfunction in the dental eruption, thus requiring more than one type of treatment. Thus, the association of clinical and radiographic examination is of extreme importance in order to have a better performance in the surgical or orthodontic approach (Table 1). The use of nitrous oxide is widely used to control patients' sedation in the outpatient

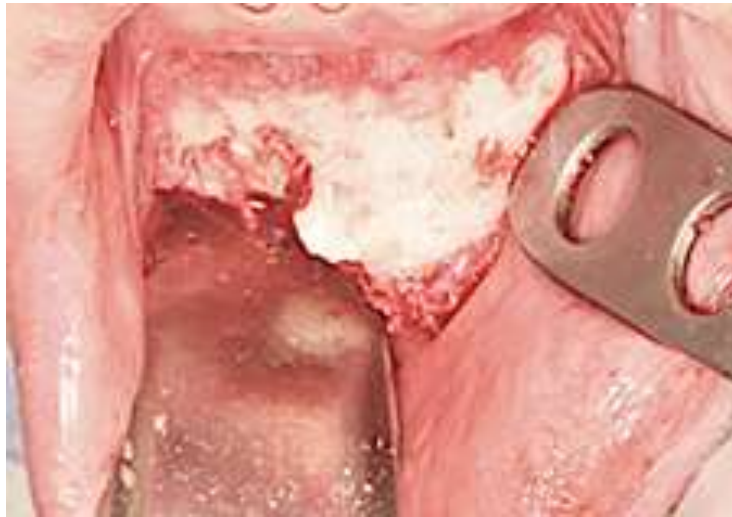

Plate 5. Fragile and brittle bone.

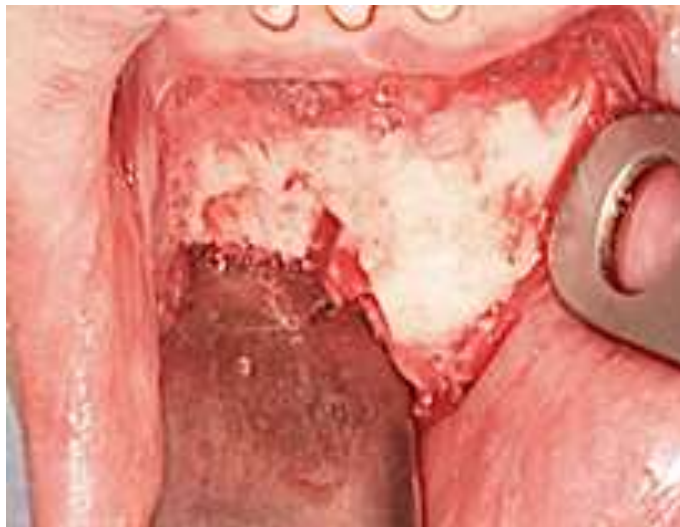

Plate 6. Fragile and brittle bone.

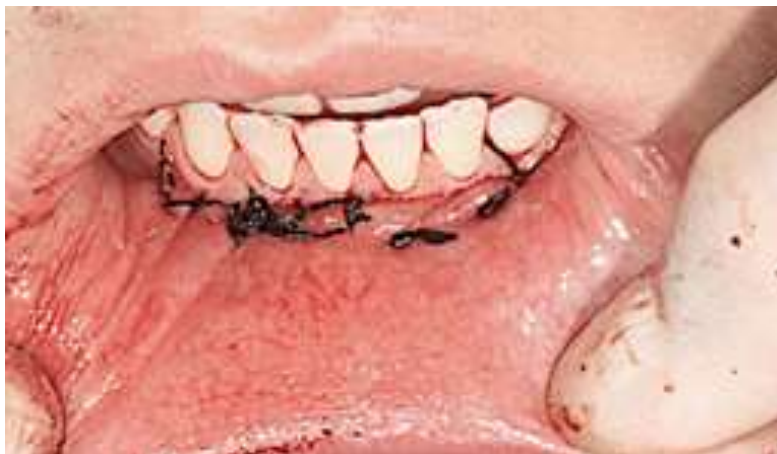

Plate 7. Suture after canine removal.



Plate 8. Pulse oximeter.

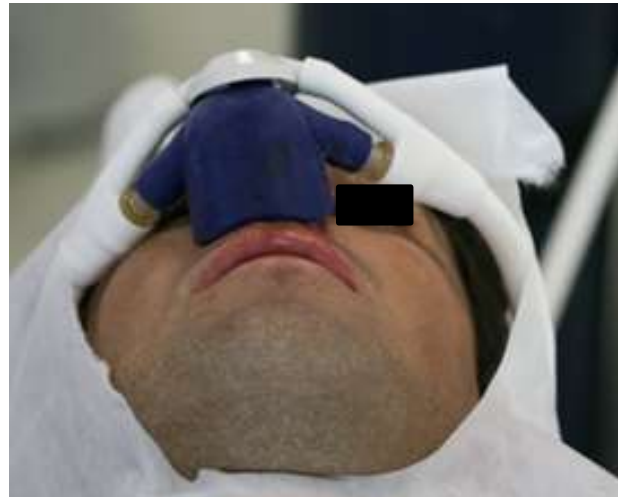

Plate 9. Nitrous oxide inhalation mask.

setting, however, it has low power and a complement must be used to control pain.

DISCUSSION

The etiology of dental organ impaction in gnathic bones can be subdivided into three groups: systemic, local, and periodontal factors. It can be weighed when the germ of the dental element also undergoes disturbances during the period of formation of the same (Lele and Modi, 2013). In cases that have impactions of dental elements in the mandible, that needs an orthosurgical approach, the risk of gingival resection increases. Because it is a region that will have a bone loss and consequently a low in the gingival tissue (Mazinis et al., 2012). Some pathology that affects the stomatognathic system may interfere with the correct eruption of dental elements. The dentigerous cyst is a benign lesion of asymptomatic, intra-osseous

epithelial lining of odontogenic origin. This pathology can interrupt the cycle of eruption of the dental germs, leading to an impaction of the same. The ossupialization and consequently the enucleation of this cyst is one of the surgical maneuvers to solve the problem. Subsequently, the orocirurgico treatment is recommended so that it stabilizes the tooth to the normal place (Park et al., 2013). Odontomas are odontogenic origin tumors characterized by a mass of dentinoid tissue that presents of two types: complex and compound. It can be developed in both jaw and maxilla and can be detected by radiographic examination. Disorders of eruption of the teeth and impaction of the teeth are often associated (Prakash et al., 2012). The adenomatoid odontogenic tumor and the ossifying cementum fibroma are lesions of large cell growth (COF) that surround the maxilla and mandibular. The COF usually affects the mandibular region presenting in several forms and being variant of adenomatoid odontogenic tumor and classic histopathological

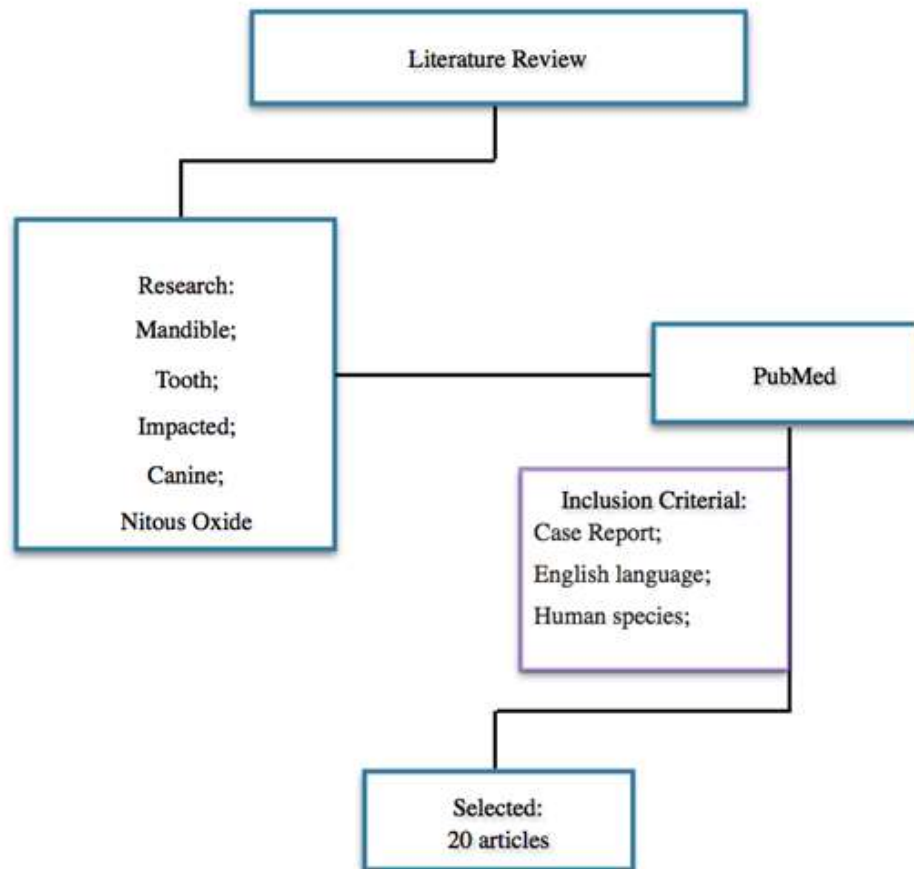


Figure 1. Schematization of the collection of works in the databases.

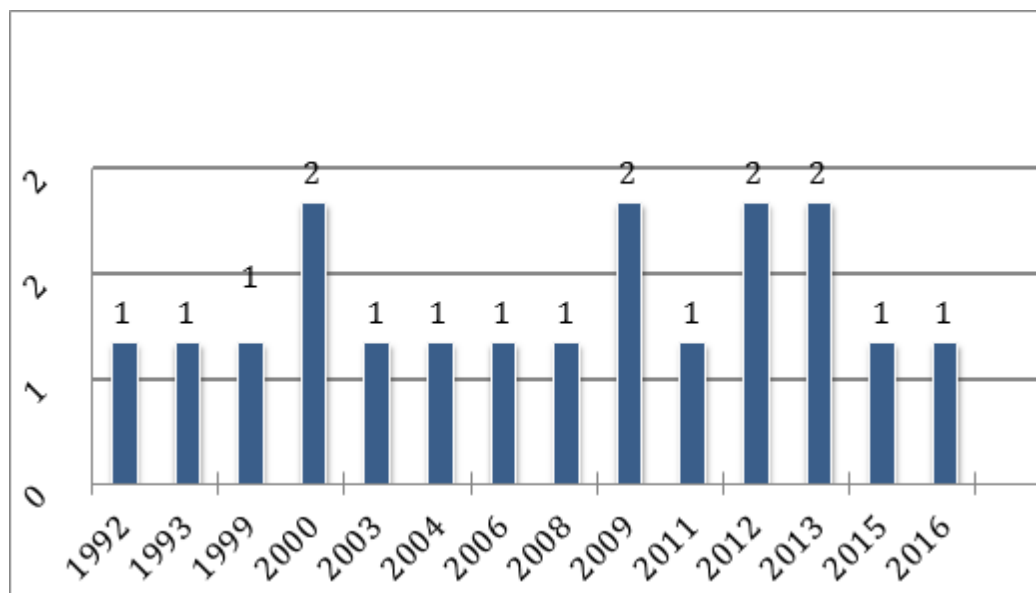


Figure 2. Number of articles in relation to years of publication.

characteristics. It is one of the lesions responsible for impacting the canine (Shinohara et al., 2014). Shpack et al. (2014), carried out a study on the prevalence of

transmigrant canines and showed through panoramic radiographs the implications it had on the surrounding teeth (Shpack et al., 2014). The transmigration of the

Table 1. Results presented by the authors' approaches.

Author / Year	Type of study	Case Numbers	Conduct
Ayuse; Kurata; Ayuse., 2015 ²	Case Report	1	Nitrous Oxide
Tarsariva et al., 2015 ³	Case Report	1	Orthodontic
Waxman., 2015 ¹⁷	Case Report	1	Nitrous Oxide
Shpack et al., 2014 ¹²	Case Report	1	Orthodontic Surgery
Trivedi et al., 2014 ¹⁵	Case Report	1	Orthodontic
Shinohara et al., 2014 ¹³	Case Report	1	Nitrous Oxide
Lau; Whang; Bister., 2013 ⁷	Case Report	1	Orthodontic
Agarwal et al., 2013 ¹	Case Report	1	Orthodontic
Cozzani et al., 2013 ⁴	Case Report	1	Orthodontic
Yucel et al., 2013 ¹⁸	Case Report	1	Orthodontic Surgery
Lele et al., 2013 ⁸	Case Report	1	Surgery
Park; Tai; Lida., 2013 ¹⁰	Case Report	1	Orthodontic
Vieira et al., 2013 ¹⁶	Case Report	1	Orthodontic
Tanchyk A; Tanchyk A., 2013 ¹⁴	Case Report	1	Nitrous Oxide
Mazinis et al., 2012 ⁹	Case Report	1	Orthodontic
Prakash et al., 2012 ¹¹	Case Report	1	Surgery
Kontham U; Kontham R; Mistry., 2012 ⁶	Case Report	1	Surgery
Santos et al., 2017 ⁵	Case Report	1	Nitrous Oxide

canines is included when part of the long axis passes through the midline. 0.17% of impacted canines are considered to be tranmigrant. These teeth can impact other adjacent teeth; depending on their im- clination can generate radicular rabsorption, however, being considered a rare situation (Tanchyk, 2013). The literature is very concise in regard to the surgical and orthodontic treatment of the teeth in an ectopic position, since it can use the removal of the impacted dental element, removal of the adjacent element, vertical movement through mechanical force and, finally, Transplantation. Some segmental and auxiliary orthodontic techniques with wire flexion are also suggested in the literature Tarsariya, 2015). The treatment plan should be well delineated by the multidisciplinary team, where most of the time will be the surgeon along with the orthodontist. The orthodontic treatment is quite complex, and when there is an associated canine associated with the deciduous canine still belonging to the alveolus, it is possible to perform the extraction of the deciduous dental element and later to perform the eruption of the impacted tooth by mechanically traction. The use of the modified lip apparatus to apply a forced eruption and anchorage brings a great functional and aesthetic result for the patient (Trivedi, 2014).

The jaw presents a complex anatomy filled with anatomical accidents and noble structures important, with that being a very limited surgical area. Impaction of canines in this region becomes a center of attention at the time of the treatment plan, since the disposition of the teeth may be closely related to the surrounding roots and a greater degree of difficulty in its withdrawal. It is rare cases of canine impaction and mandibular insivo in the same period of time, bringing greater complexity to the extraction of these elements (Vieira, 2013). Malocclusion and dental crowding associated with an impacted canine,

the literature shows that orthodontic treatment can be performed, where it recommends the anteriorization of the upper and lower dental elements, in order to perform the expansion of the dental arches. With this, creating space for the disinclusion of the impacted canine to occur (Waxman, 2015). Surgical therapy was approached by the characteristics of the dental element presented, once the position of the previous, it does not return to the normal place physiologically and in the orthodontic treatment (Yücel et al., 2013). After that, the hypothesis of permanence of the tooth in the place was discarded, since the literature reports the potential of these teeth included to generate secondary pathologies through inflammatory processes (Pita-Neto et al., 2015; Sandoval, 1993).

CONCLUSION

Through the data presented in the literature and the clinical experience, it is concluded that there are several forms of therapeutic approach for canine treatment included, since it depends on physiological and biomechanical factors that the dental element can behave in a certain period of time. With regard to the included teeth that it is not possible to go to the place of its normality, in order to disengage its function, the surgical treatment is the most indicated, since the dental element included can generate secondary pathologies of infectious origin. Further research on the pathophysiology of the permanence of dental elements should be carried out in order to elucidate some doubts about these pathologies.

REFERENCES

- Agarwal S, Shah N, Yadav S, Nanda R (2013). Correction of bilateral impacted mandibular canines with a lip bumper for anchorage reinforcement. *Am. J. Orthod. Dentofacial. Orthop.*143(3):393-403.

- Ayuse T, Kurata S, Ayuse T (2015). Anaphylactoid-like Reaction to Midazolam During Oral and Maxillofacial Surgery. *Anesth. Prog.* 62(2): 64-65.
- Cozzani G, Cozzani P, Mazzotta L, Cozzani M (2013). Non-surgical, non-extractive treatment of a severe class III malocclusion in permanent dentition: Follow-up of a case 24 years post treatment. *Int. Orthod.* 11(4): 457-73.
- Curl C, Boyle C (2012). Sedation for patients with movement disorders. *Dent Update*, 39(1):45-8.
- Santos IKS, Matos JDM, Cavalcante-Pereira N, Franco JMPL, Vardiero VA, Vasconcelos JEL (2017). Supernumerary Tooth Removal Using Nitrous Oxide - Case Report. *Int. J. Inform. Res. Rev.* 04(05): 4164-4168.
- Lau CK, Whang CZ, Bister D (2013). Orthodontic uprighting of severely impacted mandibular second molars. *Am. J. Orthod. Dentofacial Orthop.* 143(1): 116-24.
- Lele GS, Modi D (2013). Impeded eruption of mandibular canine. *J. Contemp. Dent. Pract.* 14(5): 963-7.
- Mazinis E, Zafeiriadis A, Karathanasis A, Lambrianidis T (2012). Transmigration of impacted canines: prevalence, management and implications on tooth structure and pulp vitality of adjacent teeth. *Clin. Oral Investig.* 16(2): 625-32.
- Park JH, Tai K, Iida S (2013). Unilateral delayed eruption of a mandibular permanent canine and the maxillary first and second molars, and agenesis of the maxillary third molar. *Am. J. Orthod. Dentofacial Orthop.* 143(1):134-139.
- Prakash AR, Reddy PS, Rajanikanth RRM (2012). Concomitant occurrence of cemento-ossifying fibroma and adenomatoid odontogenic tumor with bilateral impacted permanent canines in the mandible. *Indian J. Dental Res.* 23(3): 434-5.
- Shinohara M, Hirose Y, Boku A, Kimura KR, Morimoto Y, Niwa H (2014). Anesthetic management of a patient with adrenoleukodystrophy. *Masui.* 63(1),p.91-93.
- Shpack N, Davidovitch M, Vardimon AD, Mardinger O, Sarne O (2014). An ortho-surgical approach to severe impaction using bone crestal bridge: a case report. *Quintessence Int.* 45(4): 313-318.
- Tanchyk A, Tanchyk A. (2013). The absolute contraindication for using nitrous oxide with intraocular gases and other dental considerations associated with vitreoretinal surgery. *Gen. Dent.* 61(6): 6-7.
- Tarsariya VM, Jayam C, Parmar YS, Bandlapalli A (2015). Unusual intrabony transmigration of mandibular canine: case series (report of 4 cases). *BMJ Case Rep.*
- Trivedi B, Jayam C, Bandlapalli A, Patel N (2014). Surgical and orthodontic management of a horizontally impacted permanent mandibular canine: timing is vital. *BMJ Case Rep.*
- Vieira BB, Sanguino ACM, Moreira MR, Morizono EN, Matsumoto MAN (2013). Surgical-orthodontic treatment of Class III malocclusion with agenesis of lateral incisor and unerupted canine. *Dent. Press J. Orthod.* 18(3): 94-100.
- Waxman BN (2015). A 13-Year-Old Girl in Trigeminy During Anesthesia for Outpatient Dental Surgery: A Case Report. 2015. *Anesth. Prog.* 62(3):110-3.
- Yücel Ö, Yildirim G, Tosun G, Müge Baka Z, Bedii Göyenci Y, Günhan Ö (2013). Eruption of impacted permanent teeth after treatment of a dentigerous cyst: a case report. *J. Dent. Child (Chic)*. 80(2):92-6.
- Pita-Neto IC, Franco JMPL, Bringel RJS, Santana MDR, Batista HMT, Pita P, Soares ECS, Abreu LC, Rodrigues LMR (2015). Transnasal Removal of Ectopic Supernumerary Tooth from Cleft Patient. *Int. Arch. Med.* 8(197): 1-5.
- Sandoval VA (1993). Nitrous oxide: a serious look at laughing gas. 1993. *Tex. Dent. J.* 110(5):13-6.